

Acute Toxoplasmosis Mimicking Melanoma Metastases: Review of Conditions Causing False-Positive Results on ¹⁸F-FDG PET/CT

K. Ivanova^a K. Glatz^b A. Zippelius^c G. Nicolas^d P. Itin^a

Departments of ^aDermatology, ^bPathology, ^cMedical Oncology and ^dNuclear Medicine, University Hospital Basel, Basel, Switzerland

Key Words

Toxoplasmosis · Malignant melanoma · Fluorine-18-fluorodeoxyglucose positron emission tomography-computed tomography

Abstract

Invasive malignant melanoma is the most common fatal form of skin cancer. Fluorine-18-fluorodeoxyglucose positron emission tomography-computed tomography demonstrates a very high sensitivity and specificity for the detection of melanoma metastases. Here, we report an unusual case of toxoplasma lymphadenitis in a male adult patient mimicking a malignant cervical lymphadenopathy. Toxoplasmosis is a zoonosis caused by the intracellular parasite *Toxoplasma gondii*, which is usually asymptomatic in immunocompetent hosts.

Copyright © 2013 S. Karger AG, Basel

Case Report

In July 2011, a 46-year-old male patient complained about a tender nodule on the jaw. At this time the patient felt tired and weak, and he reported a weight loss of 7 kg during the last 6 months. At that time, he did not take any medication and did not show any signs of infection or other systemic symptoms such as fever or night

sweats. His medical history was remarkable for malignant melanoma on the left ear in May 2009, with tumor thickness Breslow 0.98 mm, Clark level IV, which had been treated with local surgical excision margins of 1 cm. Sentinel lymph node biopsy and PET/CT did not show any signs of metastatic disease (fig. 1A). The staging work-up revealed pT1aN0M0, disease stage IA according to the American Joint Committee on Cancer 2009. The patient's personal history was positive for ligament rupture on the right leg in 1982. The patient owns a pet cat.

On physical examination, we found a tender 2-cm enlarged submental lymph node on the left side in the draining area of the primary melanoma. The melanoma scar, skin, mucous membranes and genital area appeared normal. Laboratory findings including a complete blood cell count with leukocyte differential count, chemistry panel, inclusive CRP, creatine kinase, liver enzymes, HIV screening and S-100 were normal. Cervical sonography showed two neighboring, inhomogeneous, hypoechogenic and hyperperfused submental lymph nodes with a size of 2.6 × 0.9 × 1.1 cm on the left side, which had a round shape and showed absent fat hilum. They were suspicious for malignancy. Another lymph node, on the right side, with size of 0.3 cm appeared abnormal because it was hypoechogenic and hyperperfused. In our case, the

result of the fine-needle aspiration (FNA) was nonspecific. It consisted of predominantly small cleaved lymphocytes, occasional noncleaved cells, very few tingible body macrophages, and slightly atypical histiocytes as in reactive lymph node hyperplasia. On PET/CT disseminated lymphadenopathy (submental, cervical, axillar, intrahilar, mediastinal, mesenteric, supraininguinal, inguinal) and multiple lung nodules have been documented (fig. 1B). Based on these findings we suspected metastatic melanoma and performed a lymphadenectomy. However, the histopathologic examination of both submental lymph nodes revealed the classic signs of the so-called Piringier-Kuchinka disease. It is characterized by the presence of epithelioid cell granulomas, monocytoïd cells, sinus histiocytosis and numerous tingible body macrophages in the germinal centers (fig. 2). These histological findings are highly specific for toxoplasmosis. The serological tests demonstrated high positive IgM and IgG antibodies with low IgG avidity, a typical constellation for an acute infection with *Toxoplasma gondii*. On this clinicopathological and serological basis, we confirmed the diagnosis of acute toxoplasmosis. We did not treat the infection, because our patient was immunocompetent. To be sure that none of the lymph nodes persist and the infection resolves, PET/CT has been repeated 3 months later and the disseminated lymphadenopathy

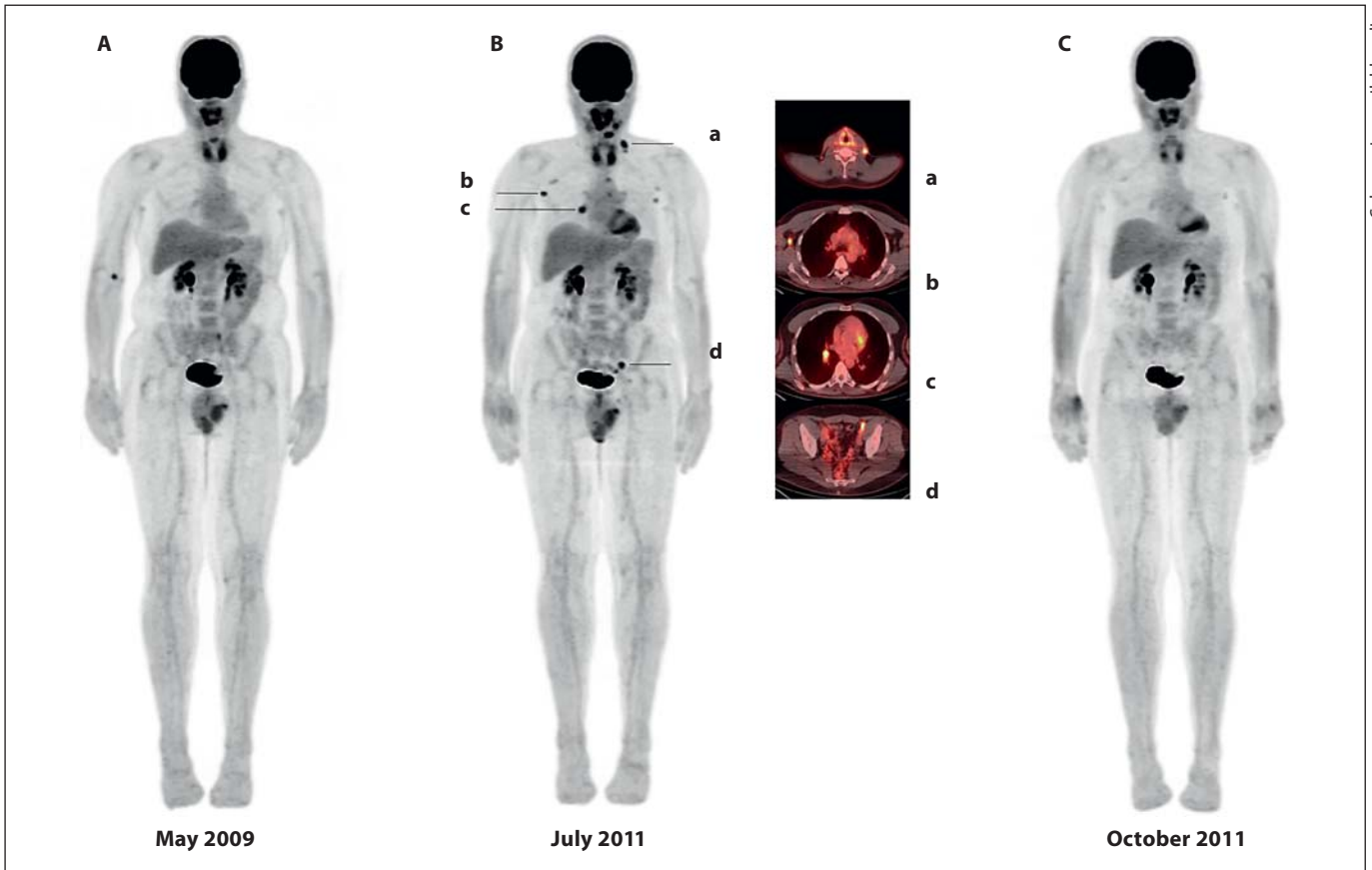
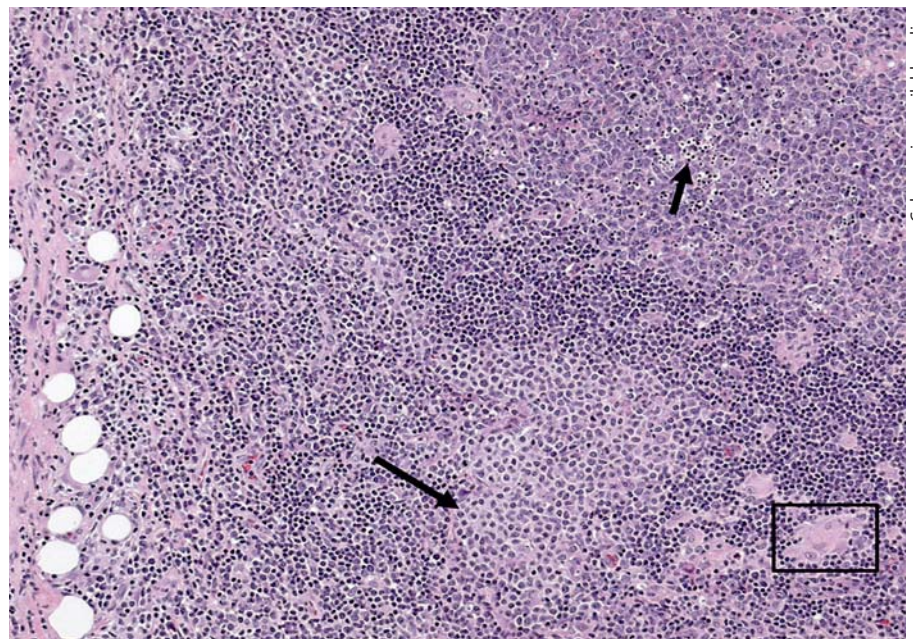


Fig. 1. **A** Maximum intensity projection of the initial whole-body ^{18}F -FDG PET/CT showing no suspicious foci of uptake. **B** Whole body restaging showing several foci of uptake. The transaxial fusion images show area of increased uptake in the left cervical (**a**),

right axillary (**b**), right hilary (**c**) and left external iliacal (**d**) regions consistent with metastatic lymphadenopathy. **C** Spontaneous normalization of the glucose metabolism in the previously described area of increased uptake.

Fig. 2. Characteristic findings of toxoplasma lymphadenitis. Lymph node capsule with chronic inflammation on the left. Large hyperplastic follicle center with numerous tingible body macrophages (short arrow). Cluster of parafollicular B lymphocytes with abundant pale staining cytoplasm resembling monocytes (long arrow). Small epitheloid cell granuloma (frame). HE. $\times 100$.



cleared (fig. 1C). The patient's cat has never had any symptoms of toxoplasmosis and the serologic test (IgM/IgG antibodies) as well as the PCR for oocyst in feces was negative at this time. Furthermore, no family member developed signs of acute toxoplasmosis. It is still unclear how our patient contracted this infection.

Discussion

We present an unusual case of acute toxoplasmosis which mimicked a malignant cervical lymphadenopathy in the draining area of a previously treated primary melanoma causing a diagnostic pitfall.

Toxoplasmosis is an infection with worldwide distribution which is caused by the intracellular protozoan parasite, *T. gondii*. The seroprevalence of *T. gondii* differs strongly in different parts of the Earth. In the USA, a seroprevalence of 9.0% has been reported during 1999–2004 in persons 12–49 years of age [1]. In central Iran, an overall prevalence of 41.4% has been published [2] and 13.2% on Jeju Island, Korea, respectively [3]. In Europe, there is evidence that the burden of congenital toxoplasmosis is lower in Northern Europe than in the rest of the continent [4]. In cities, the prevalence of toxoplasmosis is lower than in non-metropolitan areas. It increases with age, but decreases with calendar time and varies according to geographical origin. In Switzerland, the seroprevalence for toxoplasmosis among pregnant women decreased steadily from 53% (1982–1985) to 35% (1999) [4]. Cats are the only animals in which *T. gondii* can complete its reproductive cycle. After ingestion of *T. gondii*, the parasite infects the gut epithelial cells of the cat, reproduces and is excreted as an infectious oocyst in the feces [5]. Humans acquire the infection from ingestion of oocyst-contaminated soil and water, from tissue cysts in undercooked meat, by transplantation, blood transfusion, laboratory accidents, or congenitally [1]. When non-cat species, including humans, ingest *T. gondii* oocysts, the organisms invade intestinal epithelium and disseminate throughout the body [5]. They encyst in any type of nucleated cell and can lie dormant within tissues for the life of the host. Jones et al. [6] reported that exposure to certain raw or undercooked foods and contact with kittens are risk factors for *T. gondii* infection. In immunocompetent hosts the acute *T. gondii* infection is asymptomatic. However, some patients may develop fever, mal-

aise, chills, sweats, headaches or myalgias. Reviews reveal an incidence of cutaneous toxoplasmosis <10% with a great variability of the skin lesions [7]. Vidal et al. [8] described a case of 16-year-old male patient after a stem cell transplantation which developed a subtle papular, erythematous rash erupted over his back and chest. The histology revealed an interface dermatitis with occasional necrotic keratinocytes, eligible for a graft-versus-host disease. However, *T. gondii* have been identified within the epidermal keratinocytes. Another case of toxoplasmosis occurred simultaneously with dermatomyositis has been seen in a 12-year-old boy. Within 2 weeks after initiating therapy with sulfadiazine and pyrimethamine, dramatic clinical improvement has been noted [9]. A HIV-positive patient, presenting with hard and painful nodular lesions on the arms, hands and chest, had a negative serology for *T. gondii*, but the histopathologic examination of the lesion revealed foci of macrophages containing the protozoan parasite *T. gondii* [10]. In Italy, in 1980, during a period of 3 years Binazzi and Papini [11] observed 9 patients with evidence of trophozoites in skin lesions which presented different nonspecific cutaneous manifestations as ulcerative, purpuric teleangiectatic dermatosis of the lower limbs, relapsing erythema multiforme-like eruptions, erythema anulare centrifigum, lichenoid, lenticular or nummular patches as well as migrant, erysipelas-like edematous, cyanotic dermatitis. The most common manifestation of the acute toxoplasmosis is bilateral, symmetrical, nontender cervical adenopathy, which usually resolves, but in rare cases may persist chronically. The course is benign, self-limited and lasts from weeks to months. Toxoplasmosis has long been known as a major cause of perinatal morbidity. Acute infection in pregnancy may lead to fetal infection and subsequent fetal loss or birth of a manifestly or latently infected newborn with signs of hydrocephalus, cerebral calcification or debilitating ocular disease caused by chorioretinitis or anterior uveitis [12]. Toxoplasmosis encephalitis, pneumonitis, myocarditis/pericarditis, hepatitis, or polymyositis have been reported in patients with immunosuppression [1].

The diagnosis of toxoplasmosis is traditionally based on a combination of tissue biopsy and serological studies detecting antibodies against the parasite. However, if a patient's immune system is impaired, serologic tests may be falsely negative [13]. Viguer et al. [14] presented data about the

cytological diagnosis of *T. gondii*, obtained with FNA biopsy which showed high sensitivity and specificity. A distinct histologic form of lymphadenitis observed in toxoplasmosis was described by Piringerkuchinka et al. [15] in 1958. At low magnification, there is periadenitis with capsular inflammation and scarring. Follicles are large and irregular with active germinal centers containing many tingible body macrophages. Scattered collections of pale staining parafollicular monocytoid B cells and small clusters of epithelioid histiocytes forming small granulomas are the most distinct features of toxoplasmic lymphadenitis [16]. The granulomas are smaller and less sharply defined than in sarcoidosis. Langhans giant cells or caseating necrosis is absent. Lymphadenitis in toxoplasmosis may be diagnosed in FNA cytology specimens if loosely aggregated epithelioid histiocytes and tingible body macrophages are present. The crescent-shaped organisms are only very rarely observed in aspirates except in severely immunocompromised patients.

Because of the difficulty of isolating the parasite, and the generally asymptomatic nature of the primary infection, the diagnosis of acquired toxoplasmosis in immunocompetent subjects is based on serologic tests: seroconversion to 2 isotypes (IgM and IgG antibodies) or a significant increase in the IgG titer plus IgM positivity [17]. Specific IgM is considered as an acute-phase marker. However, available assays have certain drawbacks, such as a risk of false-positive results due to antinuclear antibodies or rheumatoid factor or, owing to their high sensitivity detection of residual IgM, persistent months or even years after the primary infection [18]. Complementary techniques, including IgA detection and IgG avidity assay, can refine the date of infection. In a survey, Candolfi et al. [18] demonstrated that the IgG avidity test revealed a sensitivity of 100%, a specificity of 92.7%, a positive predictive value of 90%, and a negative predictive value of 100%. Pignaneli [19] demonstrated a high diagnostic accuracy of the real-time PCR which is an easy, accurate and rapid diagnostic technique in cases of borderline serologic tests.

The differential diagnosis of toxoplasmosis includes disorders presenting with disseminated lymphadenopathy: primary HIV infection, infectious mononucleosis, cat scratch disease and Hodgkin's lymphoma. Because the course is self-limiting and the *T. gondii* infection resolves spontaneously, immunocompetent and nonpreg-

nant patients generally do not require treatment. If the symptoms are severe or prolonged beyond a few weeks the infection can be treated with the same therapy as in immunosuppressed patients.

Melanoma incidence rates continued to increase worldwide among white men (2.1% per year) and white women (2.4% per year) during 1999 through 2008. Rates increased for men aged over 55 years and women of all ages [20]. In the United States an estimated 68,130 new cases of malignant melanoma were predicted to be diagnosed in 2010, resulting in 8,700 deaths [21]. Approximately 20% of primary lesions are located on the head and neck, although this region accounts for only 9% of the total surface area of the body. Multiple factors contribute to this anatomic predilection, including higher levels of sun exposure and melanocyte content of the skin. Mortality rates among head and neck melanomas differ by site: lesions of the scalp and neck have the highest mortality, with a 10-year survival of 60%. Tumors located on the ear, face, and eyelid have 10-year survival rates of 70, 80 and 90%, respectively [22, 23]. Advanced age, male sex, nodular morphological features, tumor thickness, ulceration, and Clark level V carry a significant risk of death for cutaneous head and neck melanoma, whereas facial melanomas have a favorable prognosis [23]. Occult lymph node metastasis is present in 15–20% of patients with melanoma of the head and neck and clinically negative nodes. According to Chai et al. [24], preoperative ultrasound (US) is not useful for identifying nodal metastasis in clinically node-negative melanoma patients undergoing sentinel node (SN) biopsy. In 471 patients, the overall sensitivity of US was 33.8%, specificity 85.7%, positive predictive value 36.5%, and negative predictive value 84.2%, respectively. The sensitivity and specificity appeared to improve somewhat with increasing Breslow depth. Sensitivity was highest for the neck, but specificity was highest for the groin [24]. However, the combination of preoperative US and US-guided FNA cytology can identify 65% of SN metastases and thus reduce the need for surgical SN procedures [25]. De Rosa et al. [22] reported a highly successful identification (93.4%) of the SN in head and neck melanoma. However, despite the technical success, this procedure results in an elevated false-negative rate (20.4%) compared with non-head and neck lesions.

In contrast to other skin cancers, melanoma is an aggressive neoplasm that may

spread in an unpredictable manner to any organs of the body. This advocates the use of whole body imaging for tumor staging, in selected groups of patients. Disease dissemination may occur by direct extension from the primary site, via lymphatic spread to regional or distant lymph nodes, or by the hematogenous route. However, lymphatic spread to the regional draining area is the most common. Malignant tumors have a higher metabolic rate than normal tissues and generally overexpress numbers of specific membrane transporter proteins such as glucose transporters. Melanoma cells usually present with a high uptake of the radiolabeled glucose analog ^{18}F -FDG and can be visualized in vivo on PET imaging [26]. When coinvestigated with CT, accurate fusion of both metabolic and anatomic information enhances the staging performance of each individual technique. Indeed ^{18}F -FDG PET/CT scanning is more accurate in the detection of melanoma metastasis than CT, MRI, or ^{18}F -FDG PET alone [27–30]. In patients with advanced melanoma, ^{18}F -FDG PET/CT is at least as sensitive and definitely more specific than anatomic imaging modalities such as CT and MRI for the detection of metastatic disease [28, 29]. Overall sensitivity and specificity of ^{18}F -FDG PET/CT in the staging of malignant melanoma are approximately 98% [31]. However, ^{18}F -FDG PET/CT lacks sensitivity for initial regional staging in stage I and IIA/B melanoma patients according to the American Joint Committee on Cancer 2009. Therefore, in primary invasive melanoma ≥ 1 mm in size, selective sentinel lymphadenectomy is considered as the standard of care approach in staging these patients. Moreover, ^{18}F -FDG uptake is not tumor specific. As interpreting physicians, we need to be aware of these false-positive and false-negative results. Technical causes of false-positive results may be due to misregistration artifact, injection artifact or imaging of metallic implants [31]. Sites of physiological ^{18}F -FDG uptake include cerebral tissue, urinary system and liver, whereas sites of physiological ^{18}F -FDG activity include brown fat, adrenal activity, uterus and ovaries. An inflammation (surgery or radiotherapy, pelvic insufficiency fractures, granulomatous disease) can be also confused with malignancy [32–34]. Inflammatory cells such as neutrophils and activated macrophages at the site of infection or inflammation actively accumulate ^{18}F -FDG. In the posttherapy setting, it has been reported that up to 40% of ^{18}F -FDG

uptake occurs in nontumor tissue. Infection is one of the most common causes of false-positive ^{18}F -FDG PET/CT findings after chemotherapy. These patients are susceptible to a wide variety of infections, including upper respiratory chest infections, pneumonia, colitis, cholecystitis and cellulitis. Reactivation of tuberculous infection can occur in immunocompromised patients postchemotherapy, and correlation with CT imaging can prevent misdiagnosis in suspected cases. Atypical fungal and parasitic infections such as cryptococcosis, pneumocystis and paragonimiasis can also present as false-positives on ^{18}F -FDG imaging [32]. Long and Smith [32] presented the case of a 67-year-old male for restaging of a laryngeal carcinoma with increased ^{18}F -FDG uptake in the left lower neck and left mediastinum. CT demonstrated lymphadenopathy in these areas. Biopsy of the left lower neck node confirmed sarcoidosis. In female patients, acute and chronic inflammation, physiologic lactation, and benign breast masses, including silicone granuloma, fat necrosis, fibroadenoma, and post-surgical changes can mimic breast cancer on ^{18}F -FDG PET and PET/CT [35]. False-negative results have been reported with marrow stimulation and in nodes adjacent to brown fat uptake.

Conclusion

Acute toxoplasmosis can mimic malignant lymphadenitis. Serologic tests and a highly specific histologic pattern provide the diagnosis of *T. gondii* infection which runs a benign self-limited course in immunocompetent patients. ^{18}F -FDG PET/CT shows very high sensitivity and specificity in staging of advanced malignant melanoma, but lacks sensitivity for initial regional staging in stage I and IIA/B melanoma patients according to the American Joint Committee on Cancer 2009. However, ^{18}F -FDG uptake is not tumor specific. Therefore, different pathologic and physiologic conditions as inflammation, infection, surgery or artifact may cause false-positive results.

Disclosure Statement

The authors have no conflicts of interest to declare.

References

- 1 Elmore SA, Jones JL, Conrad PA, Patton S, Lindsay DS, Dubey JP: *Toxoplasma gondii*: epidemiology, feline clinical aspects, and prevention. *Trends Parasitol* 2010;26:190–196.
- 2 Mostafavi SN, Ataei B, Nokhodian Z, Yaran M, Babak A: Seroepidemiology of *Toxoplasma gondii* infection in Isfahan province, central Iran: a population based study. *J Res Med Sci* 2011;16:496–501.
- 3 Hong SJ, Chong CK, Lee K, Kim TS, Hong YP, Ahn HJ, Kim HY, Ko AR, Kim YJ, Nam HW: Maintained seroprevalence of toxoplasmosis among the residents of Jeju Island, Korea. *Korean J Parasitol* 2011;49:309–311.
- 4 Boubaker K, Raeber PA, Vaudaux B, Bucher HC, Garweg JG, Hoesli I, Kind C, Hohlfeld P: Toxoplasmosis during pregnancy and infancy. A new approach for Switzerland. *Swiss Med Wkly* 2008;138(suppl 168):1–8.
- 5 Tenter AM, Heckerth AR, Weiss LM: *Toxoplasma gondii*: from animals to humans. *Int J Parasitol* 2000;30:1217–1258.
- 6 Jones JL, Dargelas V, Roberts J, Press C, Remington JS, Montoya JG: Risk factors for *Toxoplasma gondii* infection in the United States. *Clin Infect Dis* 2009;49:878–884.
- 7 Mawhorter SD, Efron D, Blinkhorn R, Spagnuolo PJ: Cutaneous manifestations of toxoplasmosis. *Clin Infect Dis* 1992;14:1084–1088.
- 8 Vidal CI, Pollack M, Uliasz A, del Toro G, Emanuel PO: Cutaneous toxoplasmosis histologically mimicking graft-versus-host disease. *Am J Dermatopathol* 2008;30:492–493.
- 9 Pollock JL: Toxoplasmosis appearing to be dermatomyositis. *Arch Dermatol* 1979;115:736–737.
- 10 Fong MY, Wong KT, Rohela M, Tan LH, Adeeba K, Lee YY, Lau YL: Unusual manifestation of cutaneous toxoplasmosis in a HIV-positive patient. *Trop Biomed* 2010;27:447–450.
- 11 Binazzi M, Papini M: Cutaneous toxoplasmosis. *Int J Dermatol* 1980;19:332–335.
- 12 Commodaro AG, Belfort RN, Rizzo LV, Muccioli C, Silveira C, Burnier MN Jr, Belfort R Jr: Ocular toxoplasmosis: an update and review of the literature. *Mem Inst Oswaldo Cruz* 2009;104:345–350.
- 13 Chen X, Remotti F, Tong GX, Gorczyca E, Hamele-Bena D: Fine-needle aspiration cytology of subcutaneous toxoplasmosis: a case report. *Diagn Cytopathol* 2010;38:716–720.
- 14 Viguer JM, Jimenez-Heffernan JA, Lopez-Ferrer P, Conzalez-Peramato, P, Vicandi B: Fine needle aspiration of toxoplasmic (Piringer-Kuchinka) lymphadenitis: a cytohistologic correlation study. *Acta Cytol* 2005;49:139–143.
- 15 Piringer-Kuchinka A, Martin I, Thalhammer O: Superior cervicalnuchal lymphadenitis with small groups of epitheloid cell proliferation. *Virchows Arch* 1958;331:522–535.
- 16 Yildirim AC, Bostanci H, Yilmaz ED, Kutluer N, Kargici H: *Toxoplasma* lymphadenitis mimicking malign axillary lymphadenopathy of a left breast mass. *Updates Surg* 2012.
- 17 Silva-Dos-Santos PP, Barros GB, Mineo JR, Silva DA, Menegaz MH, Serufo JC, Dietze R, Martins-Filho OD, Lemos EM: Flow cytometry-based algorithm to analyze the anti-fixed *Toxoplasma gondii* tachyzoites IgM and IgG reactivity and diagnose human acute toxoplasmosis. *J Immunol Methods* 2012;378:33–43.
- 18 Candolfi E, Pastor R, Huber R, Filisetti D, Villard O: IgG avidity assay firms up the diagnosis of acute toxoplasmosis on the first serum sample in immunocompetent pregnant women. *Diagn Microbiol Infect Dis* 2007;58:83–88.
- 19 Pignaneli S: Laboratory diagnosis of *Toxoplasma gondii* infection with direct and indirect diagnostic techniques. *Indian J Pathol Microbiol* 2011;54:786–789.
- 20 Simard EP, Ward EM, Siegel R, Jemal A: Cancers with increasing incidence trends in the United States: 1999 through 2008. *CA Cancer J Clin* 2012;62:118–128.
- 21 Jemal A, Siegel R, Xu J, Ward E: Cancer statistics, 2010. *CA Cancer J Clin* 2010;60:277–300.
- 22 De Rosa N, Lyman GH, Silbermins D, Valsecchi ME, Pruitt SK, Tyler DM, Lee WT: Sentinel node biopsy for head and neck melanoma: a systematic review. *Otolaryngol Head Neck Surg* 2011;145:375–382.
- 23 Golger A, Young DS, Ghazarian D, Neligan PC: Epidemiological features and prognostic factors of cutaneous head and neck melanoma: a population-based study. *Arch Otolaryngol Head Neck Surg* 2007;133:442–447.
- 24 Chai CY, Zager JS, Szabunio MM, Marzban SS, Chau A, Rossi RM, Sondak VK: Preoperative ultrasound is not useful for identifying nodal metastasis in melanoma patients undergoing sentinel node biopsy: preoperative ultrasound in clinically node-negative melanoma. *Ann Surg Oncol* 2012;19:1100–1106.
- 25 Voit C, Van Akkooi AC, Schäfer-Hesterberg G, Schoengen A, Kowalczyk K, Roewert JC, Sterry W, Eggermont AM: Ultrasound morphology criteria predict metastatic disease of the sentinel nodes in patients with melanoma. *J Clin Oncol* 2010;28:847–852.
- 26 Gillies RJ, Robey I, Gatenby RA: Causes and consequences of increased glucose metabolism of cancers. *J Nucl Med* 2008;49(suppl 2):24S–42S.
- 27 Reinhardt MJ, Joe AY, Jaeger U, Huber A, Matthies A, Bucerius J, Roedel R, Strunk H, Bieber T, Biersack HJ, Tütting T: Diagnostic performance of whole body dual modality ¹⁸F-FDG PET/CT imaging for N- and M-staging of malignant melanoma: experience with 250 consecutive patients. *J Clin Oncol* 2006;24:1178–1187.
- 28 Mottaghy FM, Sunderkötter C, Schubert R, et al: Direct comparison of [¹⁸F]FDG PET/CT with PET alone and with side-by-side PET and CT in patients with malignant melanoma. *Eur J Nucl Med Mol Imaging* 2007;34:1355–1364.
- 29 Strobel K, Dummer R, Husarik DB, et al: High-risk melanoma: accuracy of FDG PET/CT with added CT morphologic information for detection of metastases. *Radiology* 2007;244:566–574.
- 30 Pfannenbergl C, Aschoff P, Schanz S, et al: Prospective comparison of 18F-fluorodeoxyglucose positron emission tomography/computed tomography and whole-body magnetic resonance imaging in staging of advanced malignant melanoma. *Eur J Cancer* 2007;43:557–564.
- 31 Essler M, Link A, Belloni B, Mirceva V, Souvatzoglu M, Thaler M, Haller B, Hein R, Krause BJ: Prognostic value of [¹⁸F]-fluorodeoxyglucose PET/CT, S100 or MIA for assessment of cancer-associated mortality in patients with high risk melanoma. *PLoS One* 2011;6:e24632.
- 32 Long NM, Smith CS: Causes and imaging features of false positives and false negatives on F-PET/CT in oncologic imaging. *Insights Imaging* 2011;2:679–698.
- 33 Ozgiray E, Oner K, Ovul I: HIV related toxoplasmic encephalitis mimicking multiple metastasis: case report. *Turk Neurosurg* 2007;17:207–210.
- 34 Spieth K, Risse J, Kaufmann R, Gille J: Challenging cases and diagnostic dilemmas: case 3. Positron emission tomography scan mimicking lymph node metastases in a high-risk melanoma patient. *J Clin Oncol* 2002;20:3349–3351.
- 35 Adejolu M, Huo L, Rohren E, Santiago L, Yang WT: False-positive lesions mimicking breast cancer on FDG PET and PET/CT. *AJR Am J Roentgenol* 2012;198:W304–W314.